Patient Safety Themes and Trends

April 2021

SI ECGs – can you decipher them?

67 year old male, called with breathlessness, possible allergic reaction. Significant comorbidities, generally unwell off legs. No chest pain, previous history of AF.

Why was this an SI?
Patient non-conveyed and died later the same day. – the crew understood the ECG to be AF and LBBB and normal for patient. However, during investigation, the patient was not known to have LBBB, only previous AF.

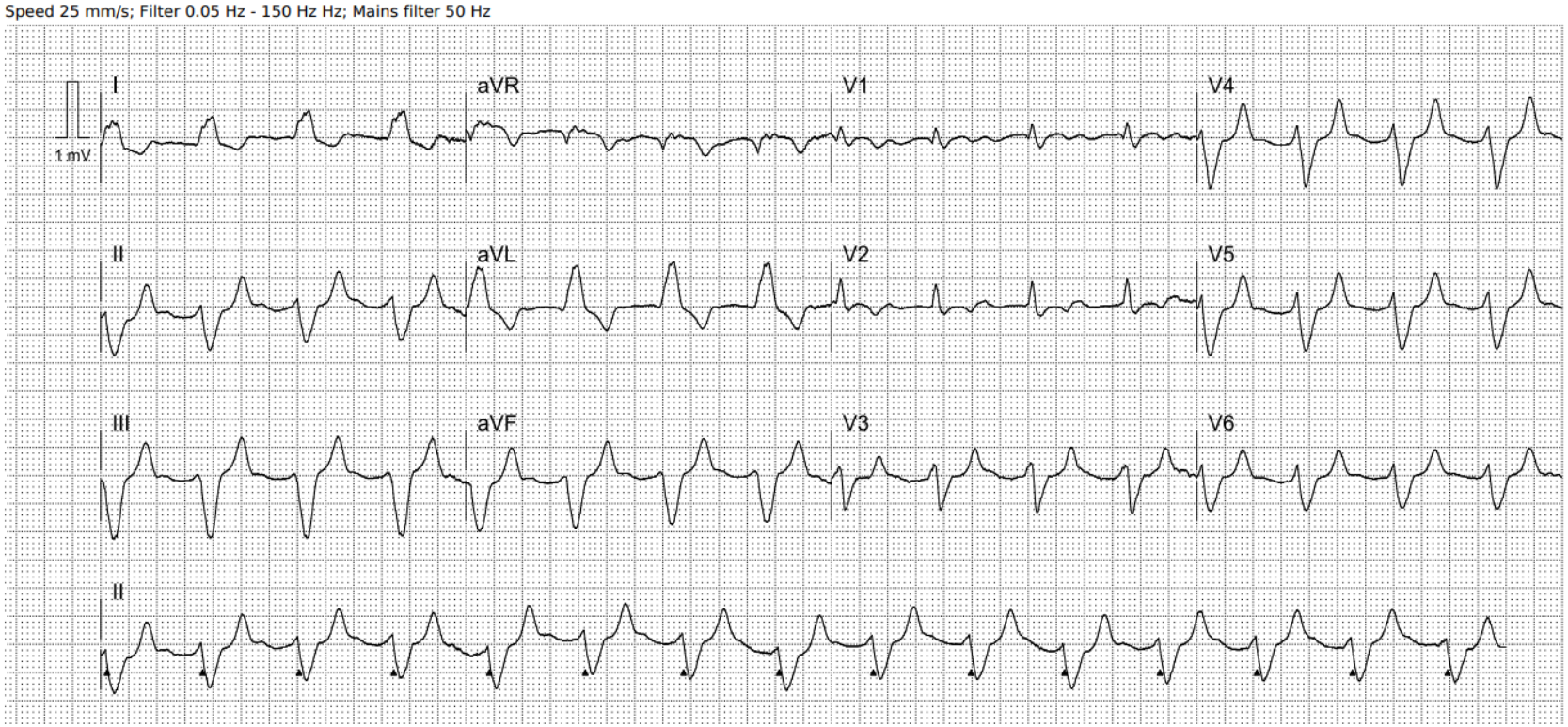

WEB182789
Hx PAF. No known hx of LBBB.
ECG does not show AF or LBBB. Possible tri-fasicular block. However, key note is abnormal ECG and unable to confirm if this is normal for patient . Some symptoms associated.

Patient Safety Themes and Trends

SI ECGs – can you depict them?

48 year old male
Original 999 call for chest pain.
On crew arrival, no chest pain.
Previous episodes of 'tachycardia'.
Appeared well on examination.

What happened – why was it an SI?

Patient was now asymptomatic and risk to patient being conveyed considered due to chemotherapy patient. Advice sought from ward staff. However, ECG not shared and changes were present. This was then not shared with the patient as part of their joint non-conveyance decision making. The patient died the next day.

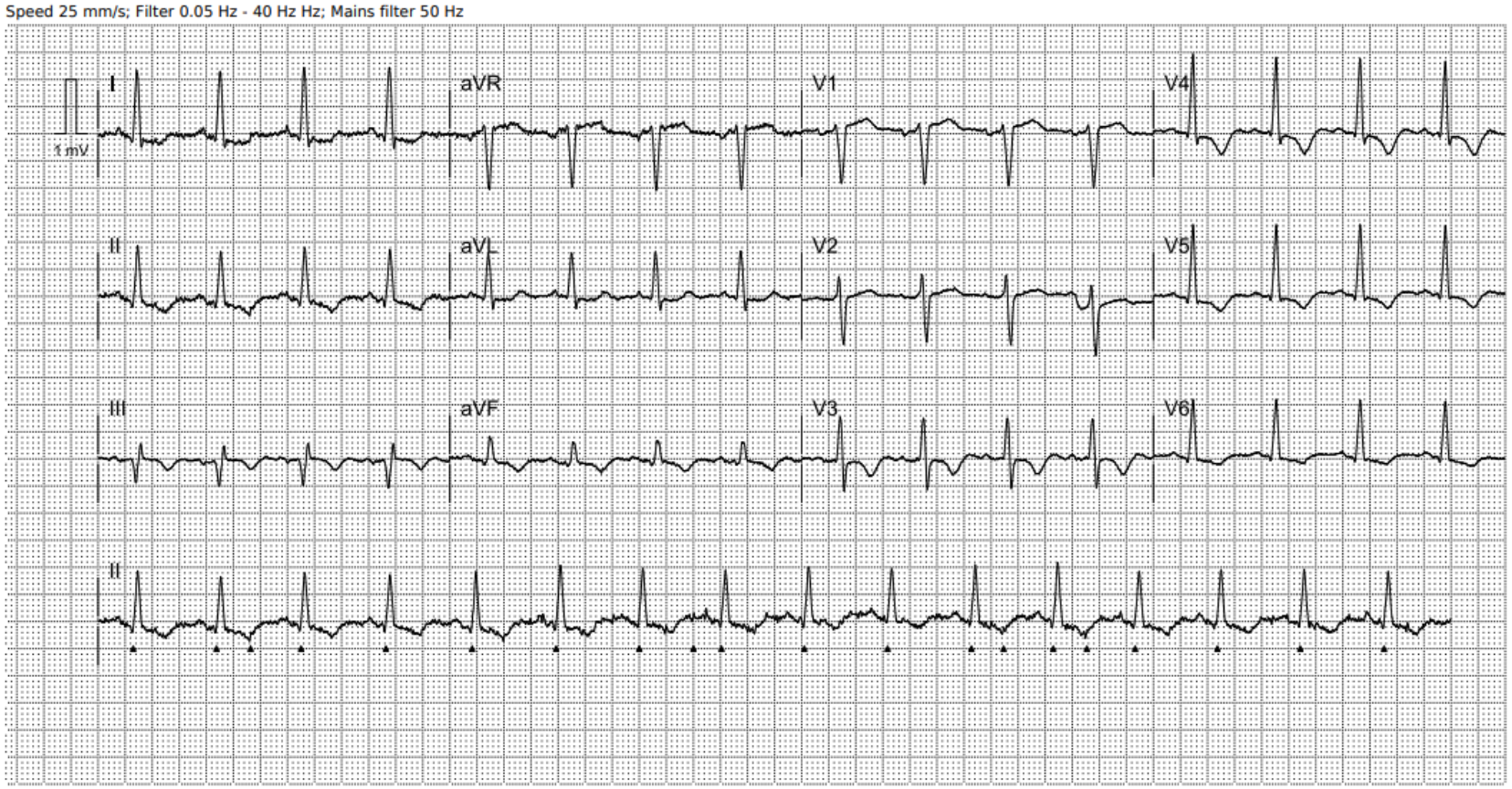

WEB176671
Ischaemic ECG signs (inverted T waves and ST depression)

Patient Safety Themes and Trends

SI ECGs – can you depict them?

91 year old male – 999 call for unresponsive episode. On crew's arrival, patient alert and orientated. Denies any pain. Observations within normal range.

What happened – why was it an SI?

Patient improved and now asymptomatic. Patient history fitted with vaso-vagal episode suggested. However, ECG changes missed. Patient attended hospital the next day and died

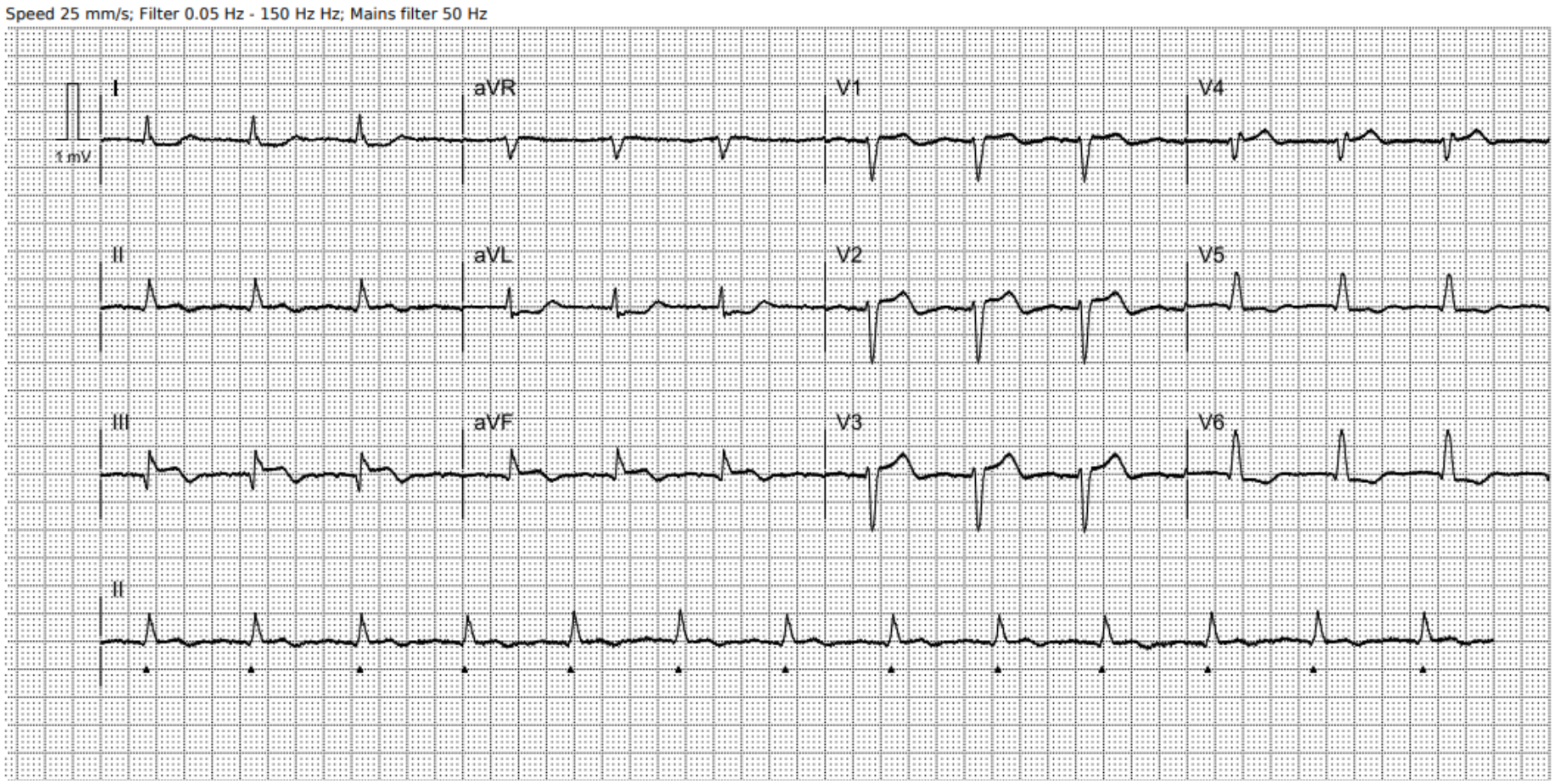

WEB178829
Inferior STEMI with reciprocal changes – PPCI later opted to not accept patient due to co-morbidities.